



## Pseudoxanthoma elasticum: a clinical, pathophysiological and genetic update including 11 novel ABCC6 mutations

N Chassaing, L Martin, P Calvas, M Le Bert and A Hovnanian

*J. Med. Genet.* 2005;42;881-892; originally published online 13 May 2005;  
doi:10.1136/jmg.2004.030171

---

Updated information and services can be found at:  
<http://jmg.bmjournals.com/cgi/content/full/42/12/881>

---

*These include:*

### References

This article cites 110 articles, 21 of which can be accessed free at:  
<http://jmg.bmjournals.com/cgi/content/full/42/12/881#BIBL>

### Rapid responses

You can respond to this article at:  
<http://jmg.bmjournals.com/cgi/eletter-submit/42/12/881>

### Email alerting service

Receive free email alerts when new articles cite this article - sign up in the box at the top right corner of the article

---

### Topic collections

Articles on similar topics can be found in the following collections

[Genetics](#) (3592 articles)  
[Dermatology](#) (411 articles)

---

### Notes

---

To order reprints of this article go to:  
<http://www.bmjournals.com/cgi/reprintform>

To subscribe to *Journal of Medical Genetics* go to:  
<http://www.bmjournals.com/subscriptions/>

## REVIEW

# Pseudoxanthoma elasticum: a clinical, pathophysiological and genetic update including 11 novel *ABCC6* mutations

N Chassaing\*, L Martin\*, P Calvas, M Le Bert, A Hovnanian



*J Med Genet* 2005;42:881–892. doi: 10.1136/jmg.2004.030171

Pseudoxanthoma elasticum (PXE) is an inherited systemic disease of connective tissue primarily affecting the skin, retina, and cardiovascular system. It is characterised pathologically by elastic fibre mineralisation and fragmentation (so called “elastorrhexia”), and clinically by high heterogeneity in age of onset and the extent and severity of organ system involvement. PXE was recently associated with mutations in the *ABCC6* (ATP binding cassette subtype C number 6) gene. At least one *ABCC6* mutation is found in about 80% of patients. These mutations are identifiable in most of the 31 *ABCC6* exons and consist of missense, nonsense, frameshift mutations, or large deletions. No correlation between the nature or location of the mutations and phenotype severity has yet been established. Recent findings support exclusive recessive inheritance. The proposed prevalence of PXE is 1/25 000, but this is probably an underestimate. *ABCC6* encodes the protein *ABCC6* (also known as *MRP6*), a member of the large ATP dependent transmembrane transporter family that is expressed predominantly in the liver and kidneys, and only to a lesser extent in tissues affected by PXE. The physiological substrates of *ABCC6* remain to be determined, but the current hypothesis is that PXE should be considered to be a metabolic disease with undetermined circulating molecules interacting with the synthesis, turnover, or maintenance of elastic fibres.

independently related to PXE skin changes by Grönblad and Strandberg in 1929.<sup>10–11</sup> Precocious atheromatosis was the last sign to be related to the condition. Carlborg reported cardiovascular elastic calcification in 29 Swedish patients with PXE in 1944.<sup>12</sup>

PXE was thought for a long time to be a primary disorder of the elastic fibre system, with candidate genes encoding structural components of the fibres (elastin, fibrillins, or other microfibril associated (glyco)proteins) or related enzymes.<sup>13–14</sup> Surprisingly, it was eventually linked to mutations in the *ABCC6* (ATP binding cassette subtype C number 6) gene.<sup>15–18</sup> *ABCC6* encodes *ABCC6*, a member of the large ATP dependent transmembrane transporter family. *ABCC6* is abundantly expressed in liver and kidney cell membranes, and to a lesser extent in other tissues affected or not by PXE (skin, vessel walls, and retina).<sup>15–19–23</sup> Even though the substrates transported by *ABCC6* remain to be determined, the association of PXE with *ABCC6* efflux transport alterations raises new and exciting pathophysiological hypotheses.<sup>22–24–25</sup> Among these, a current theory is that PXE is a systemic metabolic disease resulting from a lack or accumulation in the blood stream over time of molecules interacting with ECM synthesis, turnover, or maintenance.<sup>26</sup>

## METHODS

We searched Medline in November 2004 using the key words “pseudoxanthoma elasticum”, “PXE”, “*ABCC6*”, and “*MRP6*” and considered original papers and progress reports published after 1988. Characteristic clinical events and pathological findings in PXE have been described and reviewed in previous large series and these will be referred to as appropriate.<sup>1–5</sup> Papers updating recent progress will be commented on in more detail.

## Clinical features and management

PXE is found in all populations studied so far. Its prevalence seems higher in Afrikaners from South Africa, mainly because of a founder effect.<sup>27–28</sup> A ubiquitous female to male ratio of around 2:1 is usually reported, but there is no satisfactory explanation for this. PXE is characterised by marked clinical heterogeneity, even

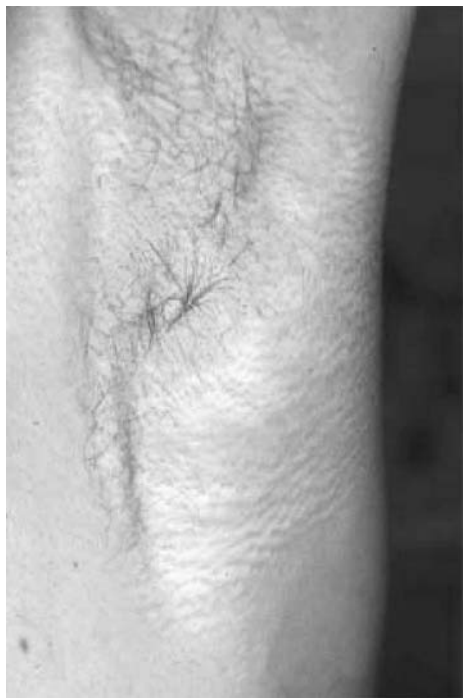See end of article for authors' affiliations

Correspondence to:  
Dr Alain Hovnanian,  
Department of Medical  
Genetics and INSERM  
U563, Pavillon Lefebvre,  
Purpan Hospital, Place du  
Dr Baylac, 31059 Toulouse  
Cedex 09, FRANCE; Email:  
alain.hovnanian@toulouse.  
inserm.fr

Received  
22 December 2004  
Revised version received  
9 April 2005  
Accepted for publication  
12 April 2005  
Published Online First  
13 May 2005

Pseudoxanthoma elasticum (PXE; MIM 264800) is an inherited systemic disease of connective tissue primarily affecting the skin, retina, and cardiovascular system.<sup>1–3</sup> PXE is characterised by elastic fibre mineralisation and fragmentation, resulting in a diagnostic pathology picture called “elastorrhexia”.<sup>1</sup> To a lesser extent, milder ultrastructural alterations of other extracellular matrix (ECM) components (collagen fibrils and glycosaminoglycans) have been demonstrated.<sup>1–6–8</sup> Cutaneous PXE was first delineated in 1896 by Darier,<sup>9</sup> who coined the term “pseudoxanthoma elasticum”, stating that the yellowish papules of PXE differed from authentic xanthomas and were related to elastic tissue fragmentation. Angioid streaks—the cardinal ophthalmological sign of PXE—were also described in the 19th century. They were

**Abbreviations:** *ABCC6*, ATP binding cassette, subfamily C, member 6; ECM, extracellular matrix; *MRP6*, multidrug resistance associated protein 6; NBF, nucleotide binding fold; PXE, pseudoxanthoma elasticum



**Figure 1** Primary skin involvement in pseudoxanthoma elasticum: axillary yellowish papules gradually coalescing to form plaques with cobblestone appearance.

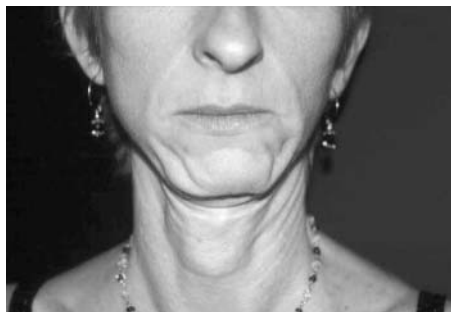

**Figure 2** Redundant axillary skin folds in pseudoxanthoma elasticum, demonstrating loss of elasticity.

between siblings, in relation to age of onset and the extent and severity of organ system involvement. Most patients have a normal life span.

### Skin involvement

The primary skin lesion is a yellowish papule of 1 to 5 mm in diameter. Such papular lesions tend gradually to coalesce to form plaques with a cobblestone appearance (fig 1). Typical skin lesions of PXE are located on the neck and in flexural areas. Cervical lesions often develop first, appearing on the lateral aspects and commonly sparing, at least initially, the medial part of the nape. They often rise between the ages of 8 and 12 years, but may be more precocious. Flexural involvement tends to start in the teenage years. The most commonly affected sites are the axillae, but involvement of the antecubital and popliteal fossae and groins is also generally noted. Involvement of anterior aspects of the wrists, umbilicus, or lumbar skin area is less common. At the point of maximum papular coalescence, skin loses its elasticity (rather than becoming hyperelastic) and typical redundant skin folds develop (fig 2). Most patients have limited skin surface involvement, but generalised "cutis laxa-like" PXE can occur and is of considerable aesthetic concern.<sup>29</sup> Recently, Lebowhl *et al* emphasised the clinical value of face involvement.<sup>30</sup> These investigators showed that horizontal and oblique mental creases are a valuable sign of PXE (fig 3). These creases have a high specificity for the diagnosis of PXE before the age of 30. Less common cutaneous manifestations have been described occasionally: acne-like lesions on the neck or the trunk, featuring comedones or inflammatory papules,<sup>31</sup> elastosis perforans serpiginosa, and reticulate pigmented rash.<sup>32</sup> In very rare instances, spontaneous resolution of PXE skin changes has been reported.<sup>1</sup> Calcinosis cutis is rarely associated with PXE, and when it occurs it is usually in association with disorders of calcium and phosphate metabolism.<sup>33-35</sup> These conditions could be particular subgroups of PXE. Mucosal lesions

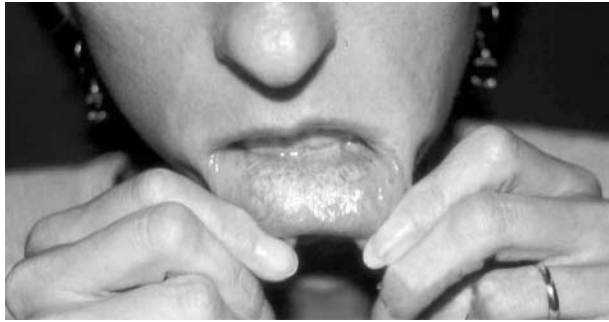

**Figure 3** Oblique mental creases in pseudoxanthoma elasticum: a valuable clinical sign for the diagnosis in young individuals.

identical to their cutaneous counterparts may be found on the inner aspect of the lower lip (fig 4), on the cheeks or the palate, or on the genitalia, but also all along the digestive tract mucous membrane.<sup>36</sup>

A skin biopsy specimen is mandatory for the diagnosis of PXE, in order to show the cardinal histological features. Aberrant clumped and fragmented elastic fibres are demonstrated in the mid-dermis by haematoxylin-eosin-safran staining, or by the use of more specific elastic stains (orcein or Verhoeff's) which colour the fibres black (fig 5). Deposition of calcium and phosphorus may be shown by the von Kossa stain.<sup>1,37</sup> Characteristic pathological features can be observed in clinically involved skin, but also in apparently normal skin. Lebowhl *et al* demonstrated occult axillary PXE in four patients who presented with premature cardiovascular disease and angioid streaks but no skin changes.<sup>38</sup> The same group previously found pathological skin findings indicative of PXE in scar biopsies from six of 10 patients with angioid streaks but without clinically characteristic skin lesions.<sup>39</sup> As an important consequence, the





**Figure 4** Mucosal lesions of pseudoxanthoma elasticum on the inner aspect of the lower lip.

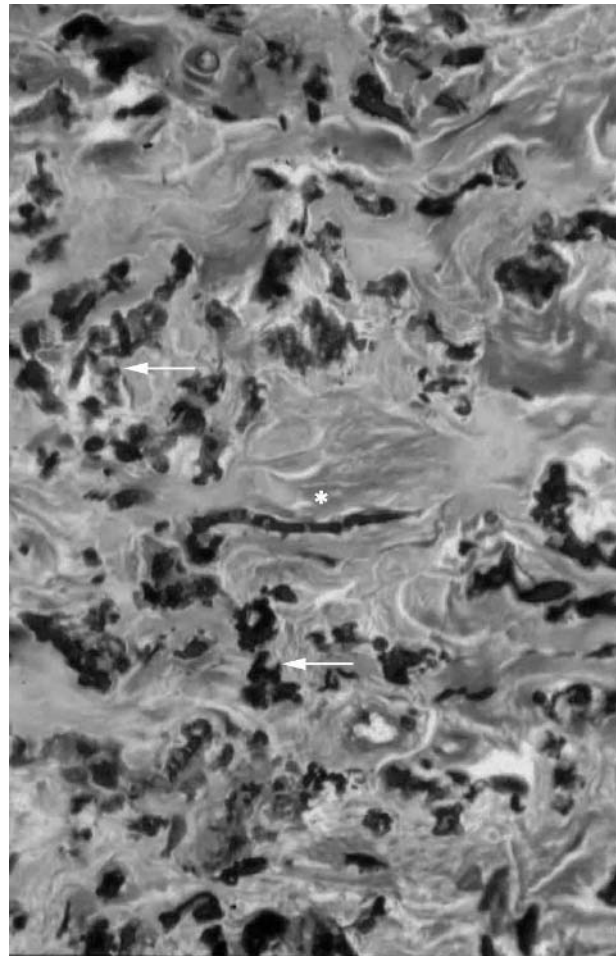
diagnosis of PXE may be suspected and made in patients without any visible skin involvement.

Ultrastructural elastic tissue alterations are seen in both lesional and non-lesional skin, in contrast to other ECM changes which are only seen in involved skin in the vicinity of altered elastic fibres.<sup>6-8</sup> Prominent abnormalities affect the elastic fibres, featuring small or large electron-dense bodies (calcifications) and holes in the core of the fibres (fig 6). Calcifications result in "fractures" of the fibres, which occur during biopsy severing. Collagen bundles display fibrils of irregular diameter and occasional flower-like features. Aggregates of filamentous material composed of elastin and proteoglycans are found close to the surface of elastic fibres.<sup>7</sup> Electron microscopic observations are misleading unless elastorrhexia has been demonstrated by optic microscopy. Indeed, the ultrastructural changes described above are not specific for PXE, and may be encountered in other inherited diseases of the ECM, but also in skin aging.

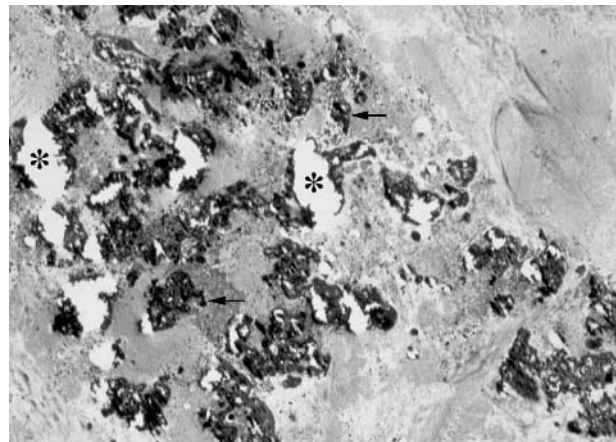
Surgical reduction of excessive and redundant skin may be envisaged in some instances for cosmetic improvement.<sup>40</sup> The long term outcome has been poorly evaluated as patient series are scarce. Viljoen *et al* reported favourable post-surgical outcome in eight female patients with a mean follow up of six years. Delayed healing and scarring occurred in two of these because of extrusion of transepidermal calcium particles.<sup>40-41</sup> The efficacy of collagen or autologous fat injections in the mental creases remain to be evaluated.<sup>41</sup>

### Eye involvement

Elastic tissue is also present in the eye, in a thin layer between the retinal pigment epithelium and the choriocapillaris known as Bruch's membrane.<sup>42</sup> The elastic fibre content of Bruch's membrane has a unique maze-like structure interwoven with collagen fibres at the side and differing from elastin structures in the skin and blood vessels. In PXE, Bruch's membrane becomes calcified and brittle. Cracks in the membrane usually occur on the eye muscle/optic nerve head track forcing lines, so they are not caused by calcification of Bruch's fibres alone. Elastic fibre alterations are responsible for acquired dehiscences and subsequent cracks in the membrane, ophthalmoscopically resulting in "angioid streaks" (fig 7). Angioid streaks are greyish irregular lines radiating outward from the optic papilla and grossly resembling vessels, hence the name.<sup>42</sup> They are optimally visualised using fluorescein or indocyanine green angiograms.<sup>43-44</sup> Angioid streaks are not in most cases responsible for visual symptoms but may be complicated by proliferation of aberrant choroidal neovessels into the subretinal space (fig 8). Neovessels have brittle walls, and this may result in recurrent, spontaneous, or trauma induced retinal haemorrhages. Neovessels and retinal haemorrhages result in macular symptoms (metamorphopsia, scotoma), peripapillary atrophy, disciform macular/foveal scarring, and

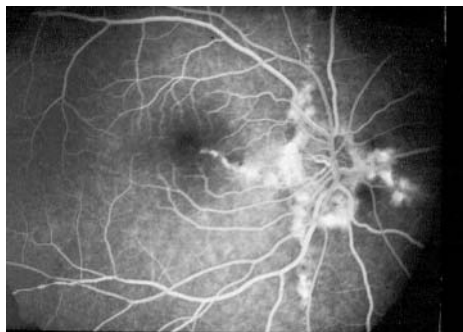

**Figure 5** Optic microscopy (orcein,  $\times 40$ ) of skin biopsy in pseudoxanthoma elasticum. Clumped and fragmented elastic fibres in the mid dermis (arrows). By comparison, a single spared fibre is indicated by a star in the middle of the figure.



**Figure 6** Electronic microscopy ( $\times 2500$ ) of skin biopsy. Electron-dense bodies (calcifications) in the core of the elastic fibres are indicated by an arrow. Some calcifications result in "fractures" of the fibres (indicated by a star).

definitive central visual loss. Eventual blindness is not uncommon in patients with PXE. Additional ocular features of PXE, such as the "peau d'orange" appearance (diffuse



**Figure 7** Angiod streaks featuring radiate cracks in the Bruch's membrane (fluorescein angiogram).

mottling of the fundus), drusen, and comet-like streaks, are less specific to PXE. However, they may precede angiod streaks for years and be helpful in the diagnosis of PXE in the presence of atypical or early skin lesions in children.<sup>1</sup>

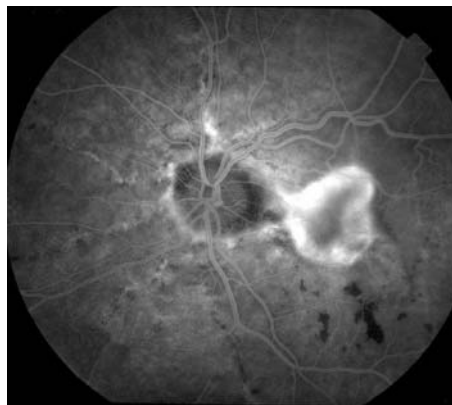
Visual complications are very difficult to treat and have the greatest impact on disability and quality of life in patients suffering from PXE. Laser therapy is used when there are submacular neovessels. This may be effective at stopping vessel proliferation or bleeding, but it causes retinal burns and subsequent scotomata. Because the anatomical lesions are reminiscent of age related macular degeneration, laser phototherapy coupled with verteporfine infusions has been attempted.<sup>45</sup> To date, the functional results of such treatment remain unclear in PXE and comprehensive analysis of the results obtained in series of treated individuals is required. Finally, surgical procedures such as macular translocation for subfoveal choroidal neovascularisation have occasionally been undertaken.<sup>46</sup> The use of antiangiogenic drugs in the prevention of choroidal neovascularisation and bleeding is in the domain of preclinical research.

### Cardiovascular involvement

Elastic fibre-rich arterial walls are also involved in the pathology of PXE, resulting in precocious and slowly evolving segmental arterial narrowing. This atheromatosis is histologically indistinguishable from other causes of atheroma such as tobacco use or chronic hypertension.<sup>47</sup> The internal elastic laminae of small and middle sized arteries are mainly involved. The slow course of vessel narrowing is associated with the development of arterial collaterality. Consequently, severe vascular symptoms are infrequent in PXE. Kornet *et al* found that a thicker and more elastic carotid artery was associated with elastin fragmentation and proteoglycan accumulation in patients with pseudoxanthoma elasticum.<sup>48</sup>

Two types of clinical manifestations may result from arterial involvement:

*Occlusive arterial disease* may be responsible for limb arteritis, coronary artery disease, digestive angina, and cerebrovascular disease. Absence of peripheral pulses is frequent, and should suggest the diagnosis of PXE in young individuals. Intermittent claudication in the lower limbs and tiredness in the upper limbs are the most common symptoms. Angina pectoris or silent coronary insufficiency may be present.<sup>49</sup> Myocardial infarction is rare, but has been reported in teenagers or young individuals.<sup>50 51</sup> Thus PXE should be considered in young patients with precocious coronary artery disease and no cardiovascular risk factors. Apart from rare reports to the contrary, surgical coronary revascularisation seems valuable. However, the left internal mammary artery may be involved in PXE and is not suitable for bypass grafting.<sup>52 53</sup> Ischaemic brain infarction in patients with PXE



**Figure 8** Proliferation of aberrant choroidal neo-vessels into the subretinal space shading the macula and resulting in central blindness (fluorescein angiogram).

is caused by small vessel disease.<sup>54</sup> This is uncommon but more prevalent than in the general population.<sup>54</sup> In the same recent large series,<sup>54</sup> an association between intracranial aneurysms and PXE was ruled out. Renovascular hypertension is probably also rare: we have only seen one case in our series of more than 60 individuals with PXE (unpublished data).

*Mucosal bleeding* may also occur as the consequence of arterial involvement, although its precise mechanism remains to be determined. Some investigators have proposed that bleeding may be related to defective submucosal vasoconstriction.<sup>4</sup> The gastrointestinal tract is by far the most common location, but case reports appear to have overestimated this severe complication.<sup>56 55</sup> The precise source of bleeding may be difficult to identify, and some haemorrhages require radical surgery. Three patients in our series have had a gastrectomy for haemostasis. Uterine or bladder bleeding has also occasionally been observed.<sup>1</sup> However, it is worth noting that there is no vascular brittleness in PXE. Spontaneous rupture of vessel walls, as seen in the vascular type of Ehlers–Danlos syndrome, has not been reported in PXE. Thus vascular surgery or radiological procedures can be carried out if indicated.

Heart involvement is uncommon in PXE. Whether valvar diseases, such as aortic or mitral stenoses<sup>56</sup> or mitral valve prolapse, are significantly associated with PXE remains to be determined using stringent diagnostic criteria.<sup>57</sup> Restrictive cardiomyopathy in relation to diffuse endocardial fibroelastosis seems to be specific for PXE but is very rare.<sup>58</sup>

**Table 1** Clinical differential diagnosis of the skin lesions of pseudoxanthoma elasticum

Feature	Conditions
Papules	Acquired pseudo-PXE related to haemoglobinopathy Skin aging (chronological and/or actinic) Elastoma, Buschke–Ollendorff syndrome Pseudo-PXE related to salpeter or D-penicillamine Papular elastorrhexia Elastosis perforans serpiginosa Perforating periumbilical PXE
Plaques or redundant skin	Elastoderma Anetoderma Cutis laxa Ehlers–Danlos syndrome (rare)
PXE, pseudoxanthoma elasticum.	

### Other manifestations

Gheduzzi *et al* recently showed that ultrastructural alterations in the elastic fibres were present in virtually all organs and tissues obtained postmortem from two PXE patients.<sup>59</sup> However, clinical manifestations only occur in tissues that are rich in elastic fibres. The lung is a remarkable exception, for which there is no explanation. Interestingly, calcification may also be present on mammograms. This might be of diagnostic value in women, and breast tumour microcalcifications are usually easily ruled out.<sup>60</sup>

Most women with PXE have normal pregnancies and deliveries. Case reports have overemphasised the risk of gastric bleeding during pregnancy, and it is certainly uncommon. Ophthalmological monitoring is, however, important in order to prevent retinal haemorrhages during labour. A recent review states that there is no basis for advising women with PXE to avoid becoming pregnant, and that most pregnancies in PXE are uncomplicated.<sup>61</sup>

### Positive and differential diagnosis

#### Positive diagnosis

A classification of PXE into clinical subtypes has been proposed previously.<sup>62</sup> Its relevance should be re-evaluated in the light of the identification of *ABCC6* as the causative gene. Up to now, the minimum criteria for the diagnosis of PXE have been the association of dermal elastorrhexia (with or without clinically visible changes) with angioid streaks. While this is most always true, we have shown in rare patients with two identified *ABCC6* mutations that one or other criterion could be absent. This observation was confirmed by recent investigations in two Italian families in which one patient with two identified mutations showed only ocular symptoms, while another had only skin involvement.<sup>63</sup> Neither a positive family history nor symptomatic atheromatosis is a constant feature of PXE, so the absence of either does not exclude the diagnosis. *ABCC6* genotyping is at present only available in specialised centres and its value for diagnosis remains to be determined (see below).

#### Dermatological differential diagnosis

Clinical and pathological recognition of skin changes suggestive of PXE is often easy. Conditions that mimic PXE clinically are summarised in table 1.<sup>64-65</sup> In most instances, pathological findings rule out the diagnosis by demonstrating increased or decreased elastic tissue without elastic fibre fragmentation or calcification. Cutaneous and articular hyperlaxity may occur in PXE but are less severe than in the Ehlers–Danlos syndromes.

### Ophthalmological differential diagnosis

Angioid streaks are not specific for PXE and have also been encountered in inherited haemoglobinopathies, Marfan's syndrome, Ehlers–Danlos syndromes, or Paget's disease of bone.<sup>42</sup> An additional and not yet well classified dominant autosomal condition has recently been described in a three generation Italian pedigree.<sup>66</sup> In this family, affected individuals had mottled fundi, angioid streaks, and drusen in various combinations, but no skin involvement suggestive of PXE, and linkage to *ABCC6* was excluded.

### Recommendations for the care of patients with PXE

At present there is no specific treatment for PXE. Management focuses on prevention, screening, and monitoring of complications. However, standards of follow up (type and rhythm) do not exist in PXE, and the identification of individuals who will develop serious complications related to PXE is difficult.

#### Prevention

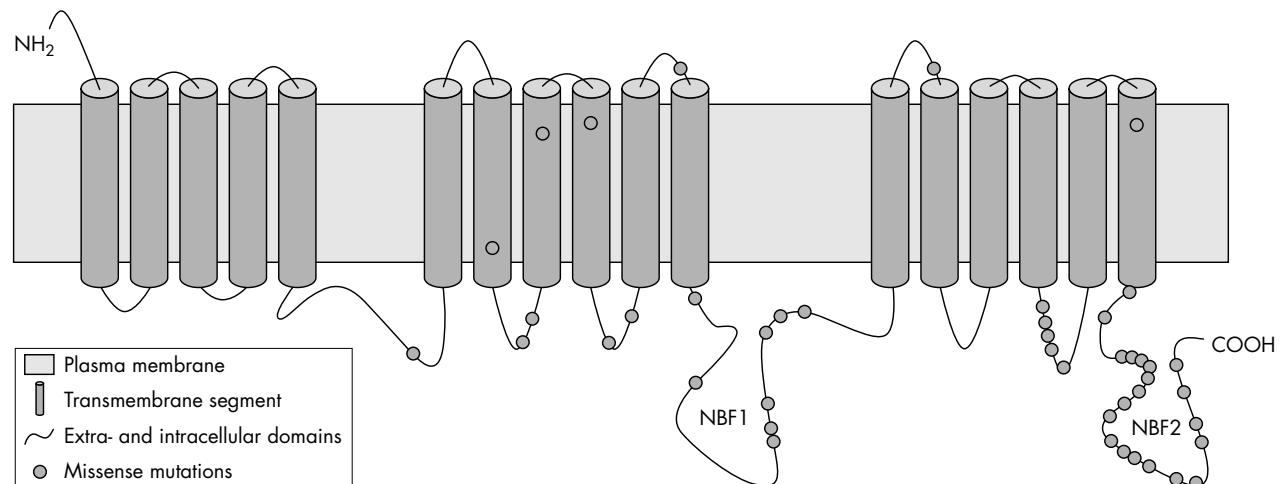
The role of diet is not clear. A single study stated that early calcium restriction could have a positive influence on the evolution of PXE by reducing the extent of mineralisation.<sup>67</sup> However, this work was based on a questionable (and unvalidated) system of severity grading and retrospective evaluation of calcium intake, which considerably reduced the validity of the author's conclusions.

Sports using balls and combat sports are contraindicated, to reduce the occurrence of facial trauma and the subsequent development of angioid streaks or retinal haemorrhages. Reduction of atheromatosis risk factors has been proposed: avoidance of smoking; control of diabetes, lipid disorders, and hypertension. Aspirin, non-steroidal anti-inflammatory drugs, or other hypocoagulant drugs should be avoided because of the risk of mucosal bleeding. The benefit to risk ratio of these drugs in the presence of cardiovascular complications is unknown in PXE, and caution is advised.

### MOLECULAR GENETICS

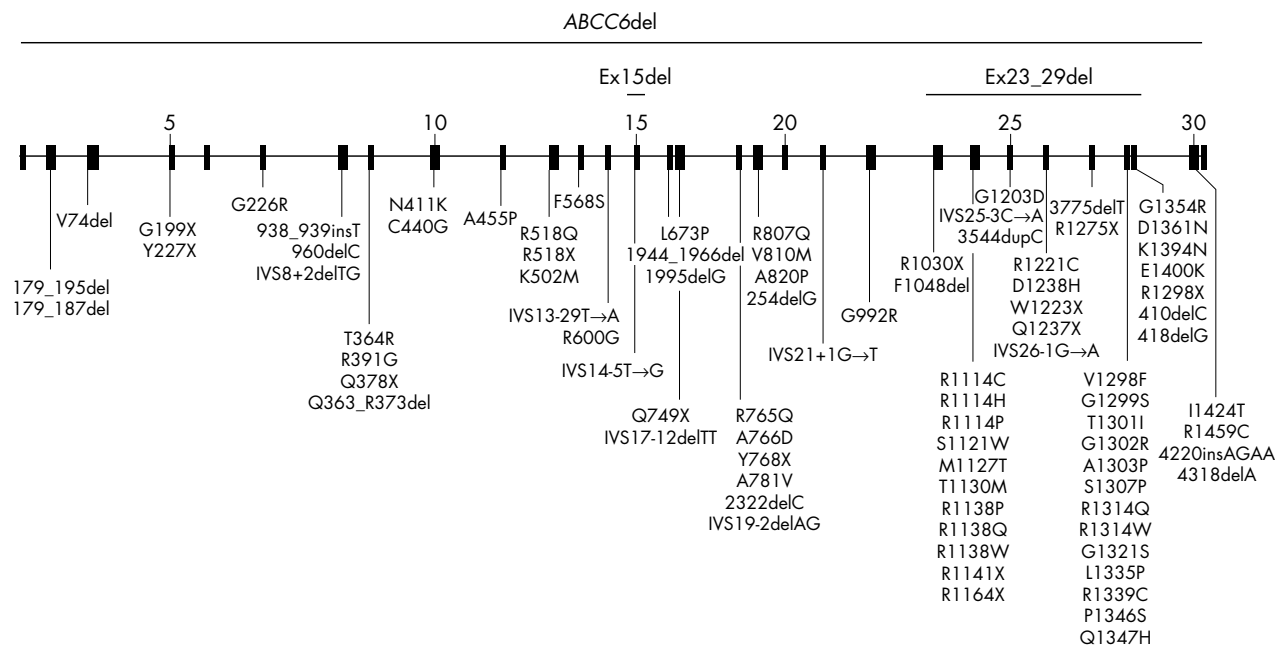
#### Identification of the PXE gene

PXE has previously been considered as a heritable connective tissue disease with primary involvement of elastic fibres. Genes encoding elastin and elastin associated proteins were therefore functional candidate genes. Subsequently, genes encoding elastin (located on chromosome 7)<sup>68</sup> and fibrillin 1 and 2 (respectively located on chromosomes 15 and 5)<sup>13</sup> were excluded by linkage analysis. Furthermore, other genes encoding members of the microfibrillar protein family and



**Figure 9** Position of the missense mutations through the *ABCC6* protein.





**Figure 10** Position of the mutations in the *ABCC6* gene.

lysyl oxidase, an enzyme participating in crosslinking of the elastic fibres, were also excluded.<sup>14</sup> More recently, the PXE gene was mapped to chromosome 16p13.1 using positional cloning approaches.<sup>69, 70</sup> Further studies refined this locus to a region of about 500 kb<sup>71, 72</sup> containing five genes with no obvious relation to the extracellular matrix of connective tissue (*ABCC1*, *ABCC6*, *pM5*, and two copies of an unknown gene subsequently identified as gene encoding the Nuclear Pore Interacting Protein (NPIP)). Direct sequencing of these genes identified pathogenic mutations in the *ABCC6* gene.<sup>15–18</sup> No mutations were identified in the other positional candidate genes.<sup>16, 73</sup>

### The PXE gene: *ABCC6*

*ABCC6* belongs to the subfamily C of ATP binding cassette (ABC) genes which includes 13 members (*ABCC1* to *ABCC13*). ABC proteins are active pumps that can transport various substrates—including ions, phospholipids, steroids, polysaccharides, amino acids, and peptides—against the substrate's concentration gradient across membranes.<sup>74</sup> They are implicated in drug and antibiotic resistance, signal transduction, protein secretion, and antigen presentation.<sup>75</sup>

*ABCC6* consists of 31 exons spanning ~73 kb. The *ABCC6* mRNA, ~6 kb in size, has an open reading frame of 4.5 kb encoding *ABCC6* (multidrug resistance associated protein 6), a 1503 amino acid protein. *ABCC6* is predominantly expressed in human liver and kidneys.<sup>21, 76</sup> Low expression levels of *ABCC6* were detected in tissues involved by PXE (skin, vessel walls, and retina), and in other tissues not affected by PXE.<sup>15, 21</sup> Two *ABCC6* pseudogenes homologous to the 5' part of *ABCC6* (exon 1 through intron 9, and exon 1 through intron 4) were recently identified and are closely mapped to *ABCC6*.<sup>77, 78</sup>

### The PXE protein: *ABCC6*

*ABCC6* is composed of three hydrophobic membrane segments comprising five, six, and six transmembrane spanning domains, respectively, and two evolutionarily conserved intracellular nucleotide binding folds (NBF) (fig 9). NBFs contain conserved Walker A and B domains, and conserved C motif critical for ATP binding and transmembrane transporter functions.

*ABCC6* was classified as a multidrug resistance associated protein because of its homology with MRP1. Indeed, *ABCC6* and MRP1 are the most closely related members of the MRP family, with 45% identity.<sup>21, 79</sup> MRP1 is a well characterised transmembrane efflux pump transporting amphipathic anionic conjugates and glucuronidated and sulphated compounds.<sup>80, 81</sup> *ABCC6* was associated, under in vitro conditions, with the MgATP dependent transport of the glutathione S-conjugate leukotriene C(4) and S-(2, 4-dinitrophenyl)glutathione, and the cyclopentapeptide BQ123.<sup>22, 24, 25</sup> *ABCC6* also confers low levels of resistance to several agents, including etoposide, teniposide, doxorubicin, and daunorubicin.<sup>24</sup> However, the role of *ABCC6* in drug resistance was questionable from the beginning.<sup>21</sup> Using several polyclonal antibodies, *ABCC6* was localised to the basolateral side of human hepatocytes and to the basolateral membranes of kidney proximal tubules,<sup>23, 82</sup> suggesting that *ABCC6* extrudes into the blood specific substrates from liver and kidney. However, the exact function and the physiological metabolites actively transported by *ABCC6* have not been yet identified.

### *ABCC6* mutations

Following the recognition of *ABCC6* as the defective gene in PXE, several groups identified mutations in PXE patients. To date 90 different disease causing mutations have been reported (79 previously published,<sup>15, 17, 18, 63, 83–89</sup> and 11 new ones in this study) in almost all the 31 *ABCC6* exons (fig 10, table 2). Among these, there are 49 missense mutations, 13 nonsense mutations, eight splicing mutations, three small insertions leading to frameshift, 14 small deletions mostly leading to a frameshift, two deletions spanning at least one exon, and one deletion of the entire *ABCC6* gene (fig 10, table 2). Although the consequences of splicing mutations have not been investigated, at least one third of the mutations introduce stop codons or frameshift that lead to premature termination of the translation. Interestingly, among the 49 different missense mutations in *ABCC6* (42 previously published and seven new ones in the present study), the majority (43) replace critical amino acids in intracellular domains (seven and 19 mutations are located in

**Table 2** ABCC6 mutations

	Nucleotide variation	Protein alteration	Location (gene)	Location (protein)	Reference
<b>Missense</b>	676 G→A	G226R	Exon 7	CL 3	This study
	1091 C→G	T364R	Exon 9	TS 7	63, 78
	1171 A→G	R391G	Exon 9	CL 4	88
	1233 T→G	N411K	Exon 10	CL 4	63, 90
	1318 T→G	C440G	Exon 10	TS 8	63
	1363 G→C	A455P	Exon 11	TS 9	86
	1505 A→T	K502M	Exon 12	CL 5	This study
	1553 G→A	R518Q	Exon 12	CL 5	63, 86, 88, 90
	1703 T→C	F568S	Exon 13	ECL 5	90
	1798 C→T	R600G	Exon 14	CL 6	63
	2018 T→C	L673P	Exon 16	NBF 1	90
	2294 G→A	R765Q	Exon 18	NBF 1	87, 90
	2297 C→A	A766D	Exon 18	NBF 1	88
	2342 C→T	A781V	Exon 18	NBF 1	This study
	2420 G→A	R807Q	Exon 19	NBF 1	This study
	2428 G→A	V810M	Exon 19	NBF1	63
	2458 G→C	A820P	Exon 19	NBF1	63
	2965 G→C	G992R	Exon 22	ECL 6	This study
	3340 C→T	R1114C	Exon 24	CL 8	63
	3341 G→A	R1114H	Exon 24	CL 8	87
	3341 G→C	R1114P	Exon 24	CL 8	90
	3362 C→G	S1121W	Exon 24	CL 8	90
	3380 C→T	M1127T	Exon 24	CL 8	63
	3389 C→T	T1130M	Exon 24	CL 8	63, 87, 88
	3412 C→T	R1138W	Exon 24	CL 8	17
	3413 G→C	R1138P	Exon 24	CL 8	90
	3413 G→A	R1138Q	Exon 24	CL 8	17, 63, 88, 90
	3608 G→A	G1203D	Exon 25	TS17	90
	3663 C→T	R1221C	Exon 26	COOH	87
	3712 G→C	D1238H	Exon 26	COOH	88
	3892 G→T	V1298F	Exon 28	NBF 2	90
	3895 G→A	G1299S	Exon 28	NBF 2	This study
	3902 C→T	T1301I	Exon 28	NBF 2	90
	3904 G→A	G1302R	Exon 28	NBF 2	87, 90
	3907 G→C	A1303P	Exon 28	NBF 2	87, 90
	3919 T→C	S1307P	Exon 28	NBF 2	This study
	3940 C→T	R1314W	Exon 28	NBF 2	90
	3941 G→A	R1314Q	Exon 28	NBF 2	90
	3961 G→A	G1321S	Exon 28	NBF 2	90
	4004 T→C	L1335P	Exon 28	NBF 2	88
	4015 C→T	R1339C	Exon 28	NBF 2	18, 63, 90
	4036 C→T	P1346S	Exon 28	NBF 2	63
	4041 G→C	Q1347H	Exon 28	NBF 2	90
4060 G→C	G1354R	Exon 29	NBF 2	78, 86	
4081 G→A	D1361N	Exon 29	NBF 2	90	
4182 G→T	K1394N	Exon 29	NBF 2	87	
4198 G→A	E1400K	Exon 29	NBF 2	63, 88	
4271 T→C	I1424T	Exon 30	NBF 2	90	
4377 C→T	R1459C	Exon 30	NBF 2	87	
<b>Nonsense</b>	595 C→T	G199X	Exon 5		89
	681 C→G	Y227X	Exon 7		84
	1132 C→T	Q378X	Exon 9		63, 78, 83
	1552 C→T	R518X	Exon 12		63, 84, 88
	2245 C→T	Q749X	Exon 17		87
	2304 C→A	Y768X	Exon 18		90
	3088 C→T	R1030X	Exon 23		63, 90
	3421 C→T	R1141X	Exon 24		15, 17, 18, 63, 78, 85, 87, 88, 90
	3490 C→T	R1164X	Exon 24		84, 85, 88
	3668 G→A	W1223X	Exon 26		88
	3709 C→T	Q1237X	Exon 26		90
	3823 C→T	R1275X	Exon 27		63
	4192 C→T	R1398X	Exon 29		90
<b>Splicing alteration</b>	IVS8+2delTG		Intron 8		This study
	IVS13-29 T→A		Intron 13		This study
	IVS14-5 T→G		Intron 14		This study
	IVS17-12delTT		Intron 17		87
	IVS18-2delAG		Intron 17		63
	IVS21+1 G→T		Intron 21		86, 90
	IVS25-3 C→A		Intron 25		88
IVS26-1 G→A		Intron 26		17, 63, 90	
<b>Insertion</b>	938_939insT	Frameshift	Exon 8		90
	3544dupC	Frameshift	Exon 25		63
	4220insAGAA	Frameshift	Exon 30		15, 87
<b>Small deletion</b>	179_187del	Frameshift	Exon 2		78
	179_195del	Frameshift	Exon 2		90



**Table 2** Continued

Nucleotide variation	Protein alteration	Location (gene)	Location (protein)	Reference
220_222del	V74del	Exon 3		88
960delC	Frameshift	Exon 8		84
1088_1120del	Q363_R373del	Exon 9		88
1944_1966del	Frameshift	Exon 16		15, 87
1995delG	Frameshift	Exon 16		90
2322delC	Frameshift	Exon 18		90
2542delG	Frameshift	Exon 19		90
3343_3345del	F1048del	Exon 23		This study
3775delT	Frameshift	Exon 27		15, 87, 90
4104delC	Frameshift	Exon 29		90
4182delG	Frameshift	Exon 29		87
4318delA	Frameshift	Exon 30		63
<b>Large deletion</b>		Exon 15		90
		Exons 23_29		84, 85, 88, 90
		ABCC6		15, 84

Nucleotide numbers are derived from cDNA *ABCC6* sequences (GenBank accession no. NM\_00171.2). CL X, cytoplasmic loop number X; COOH, C terminal portion; ECL X, extracellular loop number X; NBF X, nucleotide binding fold number X; TS X, transmembrane segment number X.

NBF1 and NBF2, respectively), four are located in transmembrane domains, and only two mutations have been identified in extracellular domains. Distribution of the missense mutations through *ABCC6* is indicated in fig 9. This distribution of mutations is consistent with the role of NBFs in ATP driven transport. Functional studies have already shown that *ABCC6* transport is abolished by missense mutations located in the NBF2.<sup>25</sup> This distribution suggests that intracellular domains different from NBFs are also functionally important, possibly through recognition of the substrate.

Although most of the 90 pathogenic mutations have been identified in one or a limited number of families, two variants (Ex23\_29del and R1141X) are recurrent mutations. The frequency of these two recurrent mutations differs according to the population studied: mutation Ex23\_29del represents ~28% of the detected mutations in the US population and ~4% in the European population, whereas mutation R1141X represents ~4% of the detected mutations in the US population and ~28% in the European population.<sup>90</sup> Furthermore, frequency of the R1141X differs between European countries (for example, 30% in the Dutch population,<sup>91-92</sup> 26% in Italian patients,<sup>63</sup> and 13% in the French population<sup>88</sup>). A common founder effect was identified for mutation R1141X in French and Italian populations.<sup>63-88</sup> We found that arginine codon 518 was a recurrently mutated amino acid in a cohort of 19 French families with PXE (11.5% of the detected mutations for each variant R518Q and R518X).<sup>88</sup> These two mutations represent 19% of the mutations detected in the Italian population.<sup>63</sup> In Japanese patients, neither R1141X nor Ex23\_29del mutations were identified, whereas mutations 2542delG and Q378X account for 53% and 25%, respectively.<sup>93</sup> In South African families of Afrikaansers, mutation R1339C represents more than half the mutations detected,<sup>28</sup> with a common haplotype indicating a founder effect.<sup>27-28</sup> These mutations are rarely identified in American or European populations.<sup>90</sup>

The detection rate in different studies varies from 0.55 to 0.83.<sup>63-87-88-90</sup> Lack of mutation detection in some patients could reflect exonic deletions (for example, deletion of exon 15), splice site mutations distant from the coding sequence, mutations in the gene regulatory sequences, or investigation of patients with acquired PXE-like syndrome not related to *ABCC6* mutations, such as seen in  $\beta$  thalassaemia and sickling syndromes (see below).<sup>94-95</sup> Locus heterogeneity of PXE is unlikely, but cannot currently be ruled out.

## CLINICAL GENETICS

### Mode of inheritance

PXE was first described as a sporadic disorder, but both autosomal recessive and autosomal dominant inheritances have been reported.<sup>3</sup> In fact, no molecular evidence for autosomal dominant inheritance has been established to date, and a body of evidence supports a common (probably exclusive) autosomal recessive inheritance of PXE. First, no family with PXE transmitted through three generations has been published. Second, both dominant and recessive forms of PXE have been linked to the same chromosomal region 16p13.1,<sup>69</sup> and *ABCC6* mutations were identified in families described with autosomal recessive or dominant inheritance. Moreover, no specific dominant mutation has been described, and the same mutations have been identified in recessive and dominant families.<sup>15</sup> Third, identification of *ABCC6* mutations established pseudodominant inheritance in two families.<sup>17-88</sup> Finally, clinical delineation of the disease may be confusing because limited manifestations can be detected in some heterozygous carriers,<sup>96</sup> and because cutaneous findings mimicking PXE, or cardiovascular manifestations, can be found in the general population, although at an older age.<sup>97</sup> A recent review questioning autosomal dominant PXE concluded that this mode of inheritance might exist, but it would then be marginal.<sup>98</sup>

### Genotype-phenotype correlation

To date, no correlation has been established between the phenotype and the nature or the position of the mutations.<sup>63-88-90</sup> A high degree of allelic heterogeneity makes such an approach difficult. Nevertheless, homozygosity or compound heterozygosity for mutations leading to a premature stop codon is not significantly associated with a more severe phenotype.<sup>88</sup> High intrafamilial phenotypic variation<sup>1-63-88</sup> is suggestive of the contribution of factors other than *ABCC6* genetic background to phenotype severity, such as nutrition, hormones, lifestyle, environmental factors, or medical history.<sup>1-67-99</sup> *ABCC6* independent modifying genetic factors may also contribute to the phenotype severity.

### Epidemiology and allelic frequencies

The prevalence of PXE in the general population is still uncertain, but estimates have increased dramatically over recent decades. A few years ago an estimated prevalence of 1 in 10<sup>5</sup> births or less could be found in textbooks. This was undoubtedly an underestimate, probably reflecting in part a

lack of knowledge of PXE by physicians. In 2000, the American patients support group PXE International proposed a prevalence of PXE of  $\sim 1/25\ 000$  in New England. According to this prevalence, the calculated frequency of heterozygosity using the Hardy–Weinberg law is 1.25% (1/80).\*

In 2002, Trip *et al* reported that the prevalence of the sole R1141X mutation was significantly increased in young individuals with coronary artery disease (3.2%), but was also frequent in the general Dutch population.<sup>100</sup> They identified eight heterozygous carriers for mutation R1141X among 1057 controls (0.76%). This mutation represents about one quarter of the mutant alleles in this population.<sup>101</sup> Thus the prevalence of heterozygous carriers in the population could be estimated to be approximately 3% (0.76% $\times 4$ ). This high rate of heterozygous carriers was unexpected. This result should be confirmed by other studies in other countries (even if PXE is a ubiquitous condition), but it suggests that the prevalence of PXE individuals (temporarily defined as individuals carrying two *ABCC6* mutations) is around 1/4450, assuming this population is in Hardy–Weinberg equilibrium.†

One critical issue is to determine whether all individuals carrying two *ABCC6* mutations have a PXE phenotype. In France (750 000 lifeborn infants/year), with a disease prevalence of 1 in 4450, 169 individuals carrying two *ABCC6* mutations should be born each year (or 30 with a prevalence of 1 in 25 000). However, far fewer than 1000 patients are recognised as having PXE in France. Do the remaining individuals have a mildly symptomatic form of PXE that does not prompt them to seek medical advice? Do they have a total absence of symptoms? The consequence of this observation is that the classical PXE phenotype may only represent a small proportion of the *ABCC6* mutation carriers.

### Heterozygous carriers

Sherer *et al* have reported on mild ophthalmological or cutaneous involvement in heterozygous carriers<sup>96</sup> but they did not indicate the frequency of this phenomenon in their cohort of patients. A few reports have emphasised the carriage of a sole *ABCC6* mutation as a cardiovascular risk factor.<sup>70 100 102</sup> In the study by Trip *et al*, mutation R1141X in *ABCC6* appeared to be an independent risk factor for coronary heart disease in young people.<sup>100</sup> This observation, if confirmed in other similar cohorts, could be of course of considerable concern for public health.

Because some PXE patients sometimes have only moderate symptoms, it can be very difficult to distinguish patients with mild PXE from heterozygous carriers with mild expression. The course and prognosis are probably not the same for these two categories, and this should prompt clinicians to consider molecular diagnosis in members of pedigrees with a patient suffering from PXE.

### Genetic counselling

PXE mode of inheritance is probably exclusively autosomal recessive. Risk for parents of an affected child is therefore one in four for another pregnancy, without the possibility of evaluating the phenotype severity. For a PXE patient the risk

\*Hardy–Weinberg law:  $p^2+2pq+q^2=1$ , with  $p$  and  $q$  being the frequency of the wild type and the mutated alleles respectively,  $p^2$  the frequency of homozygosity for the wild type allele,  $2pq$  the frequency of heterozygosity, and  $q^2$  the frequency of the disease. Here,  $q^2=1/25\ 000$ ,  $q=\sqrt{(1/25\ 000)}=0.0063$ ;  $p=1-q=1-0.0063=0.9937$ . Thus the frequency of heterozygous carriers ( $2pq$ ) can be calculated as  $2\times 0.9937\times 0.0063\sim 0.0125$  (1.25%).

† Here the frequency of heterozygous carriers ( $2pq$ )=0.03 (3%). Thus, considering  $p\sim 1$ ,  $q=0.03/2=0.015$ , and the frequency of the disease ( $q^2$ )=0.015<sup>2</sup> $\sim 2.25\times 10^{-4}\sim 1/4450$ .

of having affected children varies, in the absence of consanguinity, with the rate of heterozygous carriage in their population. In the light of the recent data, that risk could lie somewhere between 1/66 (for a rate of 1/33 heterozygous carriers (3%)) to 1/160 (for a rate of 1/80 heterozygous carriers). This risk is significant and could explain pseudo-dominant inheritance in some families.

## Novel issues in pathophysiology and perspectives

### Pathophysiology

Both elastin synthesis and degradation are accelerated in the dermis of PXE patients compared with controls, and this seems to correlate with age and with the extent of the disease.<sup>8 103 104</sup> The time dependent mineralisation of elastic fibres has been recurrently studied by several groups over the past 20 years.<sup>6–8</sup> A critical step in the pathogenesis of PXE was achieved when Baccarani-Contri *et al* revealed the mechanisms whereby PXE elastic fibres become calcified and secondarily fragmented. Using immuno-electron microscopy these investigators showed that elastic fibres had enhanced expression of normal constitutive proteins (for example, vitronectin), but also accumulated aberrant matrix proteins known for their high affinity for calcium and normally involved in mineralisation processes (such as alkaline phosphatase, bone sialoprotein, and osteonectin).<sup>105 106</sup> The investigators therefore stated that PXE was primarily a disorder of the fibroblast, in accordance with their previous results showing arguments for aberrant fibroblast behaviour. The study by Quaglino *et al* showed that PXE skin fibroblasts had altered cell–cell and cell–matrix interactions and enhanced proliferation, with synthesis capabilities in vitro.<sup>107</sup> Other biochemical reports are also in favour of a role of the fibroblast in PXE, as other matrix structural alterations have been demonstrated in addition to elastorrhexia. Aggregates of structural material containing glycosaminoglycans, as well as structural collagen fibril alterations, are seen in the vicinity of elastic fibres. Abnormalities in the metabolism of glycosaminoglycans have been found.<sup>7 108</sup>

Most of these observations were made before the identification of *ABCC6* as the PXE gene, and the outstanding question now is to find the link between the absence or the functional insufficiency of a membrane transporter in liver and kidney and the mineralisation of elastic fibres in distant organs. The hypothesis that PXE is a metabolic condition with impaired and circulating factors responsible for elastic tissue changes has been proposed.<sup>26</sup> The metabolic hypothesis does not exclude the possibility of local changes in clinically involved tissues and cells.

### $\beta$ Globin diseases: another pathway to the phenotype?

One of the most puzzling findings in the field of clinical and basic PXE research is that patients with inherited haemoglobinopathies, most often  $\beta$  thalassaemia, but also sickling syndromes, may have elastic tissue changes closely resembling PXE.<sup>95</sup> Indeed, the so called “PXE-like” clinical syndrome consists in skin, eye, and cardiovascular symptoms indistinguishable from those of “classic PXE”. Notably, these manifestations occur later in life than in patients with PXE, and their prevalence increases with advancing age. Their frequency is significant in patients with major or intermediate  $\beta$  thalassaemia: in a cohort of 100 consecutive patients, 16 had skin changes, 20 had angioid streaks, and 26 at least one of both symptoms.<sup>109</sup> The causative defect is believed to be acquired and related to the primary haemoglobinopathy.<sup>95</sup> Baccarani-Contri *et al* showed, however, that structural elastic changes were strictly identical to those they had described in “classic” PXE.<sup>110</sup> Hence, the “PXE-like” phenotype identified in a number of cases of thalassaemia is indistinguishable from “classic PXE”, but with no defect in

the *ABCC6* gene.<sup>94</sup> This raises the possibility that there is an additional pathway, independent of *ABCC6* sequence changes, leading to the PXE phenotype.

## ACKNOWLEDGEMENTS

We thank our colleagues Drs P Bonicel, F Maître, and B Arbeille for ocular, optical, and electronic microscopy pictures, respectively, and Dr O Le Saux for critically reading the manuscript.

## Authors' affiliations

**N Chassaing\***, **P Calvas**, **A Hovnanian**, Department of Medical Genetics, INSERM U563, Purpan Hospital, Toulouse, France  
**L Martin\***, Department of Dermatology, Porte-Madeleine Hospital, Orléans, France  
**M Le Bert**, Team elastogenesis and metabolism, FRE 2815, CNRS Orléans, France

\*NC and LM contributed equally to this paper

Competing interests: none declared

## REFERENCES

- Neldner KH. Pseudoxanthoma elasticum. *Clin Dermatol* 1988;**6**:1–159.
- Connor PJ, Juergens JL, Perry HO, Hollenhorst RW, Edwards JE. Pseudoxanthoma elasticum and angioid streaks. A review of 106 cases. *Am J Med* 1961;**30**:537–43.
- Pope FM. Historical evidence for the genetic heterogeneity of pseudoxanthoma elasticum. *Br J Dermatol* 1975;**92**:493–509.
- Goodman R. Pseudoxanthoma elasticum: a clinical and histopathological study. *Medicine* 1963;**42**:297–334.
- Eddy D. Pseudoxanthoma elasticum. Internal manifestations. A report of cases and a statistical review of the literature. *Arch Dermatol* 1962;**86**:729–40.
- Lebwohl M, Schwartz E, Lemlich G, Lovelace O, Shaikh-Bahai F, Fleischmajer R. Abnormalities of connective tissue components in lesional and non-lesional tissue of patients with pseudoxanthoma elasticum. *Arch Dermatol Res* 1993;**285**:121–6.
- Pasquali Ronchetti I, Baccarani Contri M, Pincelli C, Bertazzoni GM. Effect of selective enzymatic digestions on skin biopsies from pseudoxanthoma elasticum: an ultrastructural study. *Arch Dermatol Res* 1986;**278**:386–92.
- Pasquali-Ronchetti I, Volpin D, Baccarani-Contri M, Castellani I, Peserico A. Pseudoxanthoma elasticum. Biochemical and ultrastructural studies. *Dermatologica* 1981;**163**:307–25.
- Darier J. Pseudoxanthoma elasticum. *Monatshfte fur Praktische Dermatologie* 1896;**23**:609–17.
- Strandberg J. Pseudoxanthoma elasticum. *Zur Haut Geschlechtskr* 1929;**31**:689–94.
- Gronblad E. Angioid streaks—pseudoxanthoma elasticum. *Vorlaufige Mitteilung Acta Ophthalmol* 1929;**7**:329.
- Carlborg U. Study of circulatory disturbances, pulse wave velocity, and pressure pulses in larger arteries in cases of pseudoxanthoma elasticum and angioid streaks: a contribution to the knowledge of the function of the elastic tissue and the smooth muscles in larger arteries. *Acta Med Scand* 1944;**151**(suppl):209.
- Christiano AM, Lebwohl MG, Boyd CD, Uitto J. Workshop on pseudoxanthoma elasticum: molecular biology and pathology of the elastic fibers. Jefferson Medical College, Philadelphia, Pennsylvania, 10 June 1992. *J Invest Dermatol* 1992;**99**:660–3.
- Uitto J, Boyd CD, Lebwohl MG, Moshell AN, Rosenbloom J, Terry S. International Centennial Meeting on Pseudoxanthoma Elasticum: progress in PXE research. *J Invest Dermatol* 1998;**110**:840–2.
- Bergen AA, Plomp AS, Schuurman EJ, Terry S, Breuning M, Dauwerse H, Swart J, Kool M, van Soest S, Baas F, ten Brink JB, de Jong PT. Mutations in *ABCC6* cause pseudoxanthoma elasticum. *Nat Genet* 2000;**25**:228–31.
- Le Saux O, Urban Z, Tschuch C, Csizsar K, Bacchelli B, Quaglino D, Pasquali-Ronchetti I, Pope FM, Richards A, Terry S, Bercovitch L, de Paepe A, Boyd CD. Mutations in a gene encoding an ABC transporter cause pseudoxanthoma elasticum. *Nat Genet* 2000;**25**:223–7.
- Ringpfeil F, Lebwohl MG, Christiano AM, Uitto J. Pseudoxanthoma elasticum: mutations in the *MRP6* gene encoding a transmembrane ATP-binding cassette (ABC) transporter. *Proc Natl Acad Sci USA* 2000;**97**:6001–6.
- Struk B, Cai L, Zach S, Ji W, Chung J, Lumsden A, Stumm M, Huber M, Schaan L, Kim CA, Goldsmith LA, Viljoen D, Figueroa LE, Fuchs W, Munier F, Ramesar R, Hohl D, Richards R, Neldner KH, Lindpaintner K. Mutations of the gene encoding the transmembrane transporter protein ABC-C6 cause pseudoxanthoma elasticum. *J Mol Med* 2000;**78**:282–6.
- Baron JM, Holler D, Schiffer F, Frankenberg S, Neis M, Merk HF, Jugert FK. Expression of multiple cytochrome p450 enzymes and multidrug resistance-associated transport proteins in human skin keratinocytes. *J Invest Dermatol* 2001;**116**:541–8.
- Beck K, Hayashi K, Nishiguchi B, Le Saux O, Hayashi M, Boyd CD. The distribution of *Abcc6* in normal mouse tissues suggests multiple functions for this ABC transporter. *J Histochem Cytochem* 2003;**51**:887–902.
- Kool M, van der Linden M, de Haas M, Baas F, Borst P. Expression of human *MRP6*, a homologue of the multidrug resistance protein gene *MRP1*, in tissues and cancer cells. *Cancer Res* 1999;**59**:175–82.
- Madon J, Hagenbuch B, Landmann L, Meier PJ, Stieger B. Transport function and hepatocellular localization of *mrp6* in rat liver. *Mol Pharmacol* 2000;**57**:634–41.
- Scheffer GL, Hu X, Pijnenborg AC, Wijnholds J, Bergen AA, Scheper RJ. *MRP6* (*ABCC6*) detection in normal human tissues and tumors. *Lab Invest* 2002;**82**:515–18.
- Belinsky MG, Chen ZS, Shchavaleva I, Zeng H, Kruh GD. Characterization of the drug resistance and transport properties of multidrug resistance protein 6 (*MRP6*, *ABCC6*). *Cancer Res* 2002;**62**:6172–7.
- Ilias A, Urban Z, Seidl TL, Le Saux O, Sinko E, Boyd CD, Sarkadi B, Varadi A. Loss of ATP-dependent transport activity in pseudoxanthoma elasticum-associated mutants of human *ABCC6* (*MRP6*). *J Biol Chem* 2002;**277**:16860–7.
- Uitto J. Pseudoxanthoma elasticum—a connective tissue disease or a metabolic disorder at the genome/environment interface? *J Invest Dermatol* 2004;**122**:ix–x.
- De Paepe A, Viljoen D, Matton M, Beighton P, Lenaerts V, Vossaert K, De Bie S, Voet D, De Laey JJ, Kint A. Pseudoxanthoma elasticum: similar autosomal recessive subtype in Belgian and Afrikaner families. *Am J Med Genet* 1991;**38**:16–20.
- Le Saux O, Beck K, Sachsinger C, Treiber C, Goring HH, Curry K, Johnson EW, Bercovitch L, Marais AS, Terry SF, Viljoen DL, Boyd CD. Evidence for a founder effect for pseudoxanthoma elasticum in the Afrikaner population of South Africa. *Hum Genet* 2002;**111**:331–8.
- Uenishi T, Uchiyama M, Sugiura H, Danno K. Pseudoxanthoma elasticum with generalized cutaneous laxity. *Arch Dermatol* 1997;**133**:664–6.
- Lebwohl M, Lebwohl E, Bercovitch L. Prominent mental (chin) crease: a new sign of pseudoxanthoma elasticum. *J Am Acad Dermatol* 2003;**48**:620–2.
- Loche F, Raynal H, Bazex J. Acne-like eruption induced by pseudoxanthoma elasticum: effectiveness of liquid nitrogen cryotherapy. *Eur J Dermatol* 1998;**8**:63–5.
- Li TH, Tseng CR, Hsiao GH, Chiu HC. An unusual cutaneous manifestation of pseudoxanthoma elasticum mimicking reticulate pigmentary disorders. *Br J Dermatol* 1996;**134**:1157–9.
- Mallette LE, Mechanick JL. Heritable syndrome of pseudoxanthoma elasticum with abnormal phosphorus and vitamin D metabolism. *Am J Med* 1987;**83**:1157–62.
- Buka R, Wei H, Sapadin A, Mauch J, Lebwohl M, Rudikoff D. Pseudoxanthoma elasticum and calcinosis cutis. *J Am Acad Dermatol* 2000;**43**:12–15.
- Martinez-Hernandez A, Huffer WE, Neldner K, Gordon S, Reeve EB. Resolution and repair of elastic tissue calcification in pseudoxanthoma elasticum. *Arch Pathol Lab Med* 1978;**102**:303–5.
- Spinzi G, Strocchi E, Imperiali G, Sangiovanni A, Terruzzi V, Minoli G. Pseudoxanthoma elasticum: a rare cause of gastrointestinal bleeding. *Am J Gastroenterol* 1996;**91**:1631–4.
- Walker ER, Frederickson RG, Mayes MD. The mineralization of elastic fibers and alterations of extracellular matrix in pseudoxanthoma elasticum. Ultrastructure, immunocytochemistry, and X-ray analysis. *Arch Dermatol* 1989;**125**:70–6.
- Lebwohl M, Halperin J, Phelps RG. Brief report: occult pseudoxanthoma elasticum in patients with premature cardiovascular disease. *N Engl J Med* 1993;**329**:1237–9.
- Lebwohl M, Phelps RG, Yannuzzi L, Chang S, Schwartz I, Fuchs W. Diagnosis of pseudoxanthoma elasticum by scar biopsy in patients without characteristic skin lesions. *N Engl J Med* 1987;**317**:347–50.
- Viljoen DL, Bloch C, Beighton P. Plastic surgery in pseudoxanthoma elasticum: experience in nine patients. *Plast Reconstr Surg* 1990;**85**:233–8.
- Galadari H, Lebwohl M. Pseudoxanthoma elasticum: Temporary treatment of chin folds and lines with injectable collagen. *J Am Acad Dermatol* 2003;**49**(5 suppl):S265–6.
- Hu X, Plomp AS, van Soest S, Wijnholds J, de Jong PT, Bergen AA. Pseudoxanthoma elasticum: a clinical, histopathological, and molecular update. *Surv Ophthalmol* 2003;**48**:424–38.
- Guzey M, Arvas S, Akar S, Ozkan S. Indocyanine green angiographic findings in young patients with Gronblad-Strandberg syndrome. *Ophthalmologica* 2001;**215**:22–9.
- Lafaut BA, Leys AM, Scassellati-Sforzolini B, Priem H, De Laey JJ. Comparison of fluorescein and indocyanine green angiography in angioid streaks. *Graefes Arch Clin Exp Ophthalmol* 1998;**236**:346–53.
- Guidelines for using verteporfin (visudyne) in photodynamic therapy to treat choroidal neovascularization due to age-related macular degeneration and other causes. *Retina* 2002;**22**:6–18.
- Roth DB, Estafanos M, Lewis H. Macular translocation for subfoveal choroidal neovascularization in angioid streaks. *Am J Ophthalmol* 2001;**131**:390–2.
- Mendelsohn G, Bulkley BH, Hutchins GM. Cardiovascular manifestations of Pseudoxanthoma elasticum. *Arch Pathol Lab Med* 1978;**102**:298–302.
- Kornet L, Bergen AA, Hoeks AP, Cleutjens JP, Oostra RJ, Daemen MJ, van Soest S, Reneman RS. In patients with pseudoxanthoma elasticum a thicker and more elastic carotid artery is associated with elastin fragmentation and proteoglycans accumulation. *Ultrasound Med Biol* 2004;**30**:1041–8.
- Kevoorkian JP, Masquet C, Kural-Menasche S, Le Dref O, Beauflis P. New report of severe coronary artery disease in an eighteen-year-old girl with pseudoxanthoma elasticum. Case report and review of the literature. *Angiology* 1997;**48**:735–41.



- 50 **Nishida H**, Endo M, Koyanagi H, Ichihara T, Takao A, Maruyama M. Coronary artery bypass in a 15-year-old girl with pseudoxanthoma elasticum. *Ann Thorac Surg* 1990;**49**:483-5.
- 51 **Nolte KB**. Sudden cardiac death owing to pseudoxanthoma elasticum: a case report. *Hum Pathol* 2000;**31**:1002-4.
- 52 **Iliopoulos J**, Manganas C, Jepson N, Newman DC. Pseudoxanthoma elasticum: is the left internal mammary artery a suitable conduit for coronary artery bypass grafting? *Ann Thorac Surg* 2002;**73**:652-3.
- 53 **Sarraj A**, Al Homsy MF, Khouefer F. Pseudoxanthoma elasticum of the internal mammary artery. *Cardiovasc Surg* 1999;**7**:381-4.
- 54 **van den Berg JS**, Hennekam RC, Cruysberg JR, Steijlen PM, Swart J, Tijmes N, Limburg M. Prevalence of symptomatic intracranial aneurysm and ischaemic stroke in pseudoxanthoma elasticum. *Cerebrovasc Dis* 2000;**10**:315-19.
- 55 **McCreehy CA**, Zimmerman TJ, Webster SF. Management of upper gastrointestinal hemorrhage in patients with pseudoxanthoma elasticum. *Surgery* 1989;**105**:170-4.
- 56 **Fukuda K**, Uno K, Fujii T, Mukai M, Handa S. Mitral stenosis in pseudoxanthoma elasticum. *Chest* 1992;**101**:1706-7.
- 57 **Lebwohl MG**, Distefano D, Prioleau PG, Uram M, Yannuzzi LA, Fleischmajer R. Pseudoxanthoma elasticum and mitral-valve prolapse. *N Engl J Med* 1982;**307**:228-31.
- 58 **Navarro-Lopez F**, Llorian A, Ferrer-Roca O, Betriu A, Sanz G. Restrictive cardiomyopathy in pseudoxanthoma elasticum. *Chest* 1980;**78**:113-15.
- 59 **Gheduzzi D**, Sammarco R, Quaglino D, Bercovitch L, Terry S, Taylor W, Ronchetti IP. Extracutaneous ultrastructural alterations in pseudoxanthoma elasticum. *Ultrastruct Pathol* 2003;**27**:375-84.
- 60 **Bercovitch L**, Schepps B, Koelliker S, Magro C, Terry S, Lebwohl M. Mammographic findings in pseudoxanthoma elasticum. *J Am Acad Dermatol* 2003;**48**:359-66.
- 61 **Bercovitch L**, Leroux T, Terry S, Weinstock MA. Pregnancy and obstetrical outcomes in pseudoxanthoma elasticum. *Br J Dermatol* 2004;**151**:1011-18.
- 62 **Lebwohl M**, Neldner K, Pope FM, De Paepe A, Christiano AM, Boyd CD, Uitto J, McKusick VA. Classification of pseudoxanthoma elasticum: report of a consensus conference. *J Am Acad Dermatol* 1994;**30**:103-7.
- 63 **Gheduzzi D**, Guidetti R, Anzivino C, Tarugi P, Di Leo E, Quaglino D, Ronchetti IP. ABCC6 mutations in Italian families affected by pseudoxanthoma elasticum (PXE). *Hum Mutat* 2004;**24**:438-9.
- 64 **Lewis KG**, Bercovitch L, Dill SW, Robinson-Bostom L. Acquired disorders of elastic tissue: part I. Increased elastic tissue and solar elastotic syndromes. *J Am Acad Dermatol* 2004;**51**:1-21; quiz 22-4.
- 65 **Lewis KG**, Bercovitch L, Dill SW, Robinson-Bostom L. Acquired disorders of elastic tissue: Part II. decreased elastic tissue. *J Am Acad Dermatol* 2004;**51**:165-85; quiz 186-8.
- 66 **Li Volti S**, Avitabile T, Li Volti G, Meloni I, Forabosco P, Marano F, Bianca S, Renieri A. Optic disc drusen, angioid streaks, and mottled fundus in various combinations in a Sicilian family. *Graefes Arch Clin Exp Ophthalmol* 2002;**240**:771-6.
- 67 **Renie WA**, Peyeritz RE, Combs J, Fine SL. Pseudoxanthoma elasticum: high calcium intake in early life correlates with severity. *Am J Med Genet* 1984;**19**:235-44.
- 68 **Raybould MC**, Birley AJ, Moss C, Hulten M, McKeown CM. Exclusion of an elastin gene (ELN) mutation as the cause of pseudoxanthoma elasticum (PXE) in one family. *Clin Genet* 1994;**45**:48-51.
- 69 **Struk B**, Neldner KH, Rao VS, St Jean P, Lindpaintner K. Mapping of both autosomal recessive and dominant variants of pseudoxanthoma elasticum to chromosome 16p13.1. *Hum Mol Genet* 1997;**6**:1823-8.
- 70 **van Soest S**, Swart J, Tijmes N, Sandkuijl LA, Rommers J, Bergen AA. A locus for autosomal recessive pseudoxanthoma elasticum, with penetrance of vascular symptoms in carriers, maps to chromosome 16p13.1. *Genome Res* 1997;**7**:830-4.
- 71 **Le Saux O**, Urban Z, Goring HH, Csiszar K, Pope FM, Richards A, Pasquali-Ronchetti I, Terry S, Bercovitch L, Lebwohl MG, Breuning M, van den Berg P, Kornet L, Doggett N, Oit J, de Jong PT, Bergen AA, Boyd CD. Pseudoxanthoma elasticum maps to an 820-kb region of the p13.1 region of chromosome 16. *Genomics* 1999;**62**:1-10.
- 72 **Cai L**, Struk B, Adams MD, Ji W, Haaf T, Kang HL, Dho SH, Xu X, Ringpfeil F, Nancarrow J, Zach S, Schaan L, Stumm M, Niu T, Chung J, Lunze K, Verrecchia B, Goldsmith LA, Viljoen D, Figuera LE, Fuchs W, Lebwohl M, Uitto J, Richards R, Hohl D, Ramesar R. A 500-kb region on chromosome 16p13.1 contains the pseudoxanthoma elasticum locus: high-resolution mapping and genomic structure. *J Mol Med* 2000;**78**:36-46.
- 73 **Perdu J**, Germain DP. Identification of novel polymorphisms in the pM5 and MRP1 (ABCC1) genes at locus 16p13.1 and exclusion of both genes as responsible for pseudoxanthoma elasticum. *Hum Mutat* 2001;**17**:74-5.
- 74 **Kerb R**, Hoffmeyer S, Brinkmann U. ABC drug transporters: hereditary polymorphisms and pharmacological impact in MDR1, MRP1 and MRP2. *Pharmacogenomics* 2001;**2**:51-64.
- 75 **Higgins CF**. ABC transporters: from microorganisms to man. *Annu Rev Cell Biol* 1992;**8**:67-113.
- 76 **Belinsky MG**, Kruh GD. MOAT-E (ARA) is a full-length MRP/cMOAT subfamily transporter expressed in kidney and liver. *Br J Cancer* 1999;**80**:1342-9.
- 77 **Germain DP**. Pseudoxanthoma elasticum: evidence for the existence of a pseudogene highly homologous to the ABCC6 gene. *J Med Genet* 2001;**38**:457-61.
- 78 **Pulkkinen L**, Nakano A, Ringpfeil F, Uitto J. Identification of ABCC6 pseudogenes on human chromosome 16p: implications for mutation detection in pseudoxanthoma elasticum. *Hum Genet* 2001;**109**:356-65.
- 79 **Cai J**, Daoud R, Alqawi O, Georges E, Pelletier J, Gros P. Nucleotide binding and nucleotide hydrolysis properties of the ABC transporter MRP6 (ABCC6). *Biochemistry* 2002;**41**:8058-67.
- 80 **Leonard GD**, Fojo T, Bates SE. The role of ABC transporters in clinical practice. *Oncologist* 2003;**8**:411-24.
- 81 **Borst P**, Evers R, Kool M, Wijnholds J. The multidrug resistance protein family. *Biochim Biophys Acta* 1999;**1461**:347-57.
- 82 **Sinko E**, Ilias A, Ujhelly O, Homolya L, Scheffer GL, Bergen AA, Sarkadi B, Varadi A. Subcellular localization and N-glycosylation of human ABCC6, expressed in MDCKII cells. *Biochem Biophys Res Commun* 2003;**308**:263-9.
- 83 **Cai L**, Lumsden A, Guenther UP, Neldner SA, Zach S, Knoblauch H, Ramesar R, Hohl D, Callen DF, Neldner KH, Lindpaintner K, Richards RI, Struk B. A novel Q378X mutation exists in the transmembrane transporter protein ABCC6 and its pseudogene: implications for mutation analysis in pseudoxanthoma elasticum. *J Mol Med* 2001;**79**:536-46.
- 84 **Meloni I**, Rubegni P, De Aloe G, Bruttini M, Pianigiani E, Cusano R, Seri M, Mandillo S, Federico A, Bardelli AM, Andreassi L, Fimiani M, Renieri A. Pseudoxanthoma elasticum: Point mutations in the ABCC6 gene and a large deletion including also ABCC1 and MYH11. *Hum Mutat* 2001;**18**:85.
- 85 **Ringpfeil F**, Nakano A, Uitto J, Pulkkinen L. Compound heterozygosity for a recurrent 16.5-kb Alu-mediated deletion mutation and single-base-pair substitutions in the ABCC6 gene results in pseudoxanthoma elasticum. *Am J Hum Genet* 2001;**68**:642-52.
- 86 **Uitto J**, Pulkkinen L, Ringpfeil F. Molecular genetics of pseudoxanthoma elasticum: a metabolic disorder at the environment-genome interface? *Trends Mol Med* 2001;**7**:13-17.
- 87 **Hu X**, Plomp A, Wijnholds J, Ten Brink J, van Soest S, van den Born LJ, Leys A, Peek R, de Jong PT, Bergen AA. ABCC6/MRP6 mutations: further insight into the molecular pathology of pseudoxanthoma elasticum. *Eur J Hum Genet* 2003;**11**:215-24.
- 88 **Chassaing N**, Martin L, Mazereeuw J, Barrie L, Nizard S, Bonafe JL, Calvas P, Hovnanian A. Novel ABCC6 mutations in pseudoxanthoma elasticum. *J Invest Dermatol* 2004;**122**:608-13.
- 89 **Yoshida S**, Honda M, Yoshida A, Nakao S, Goto Y, Nakamura T, Fujisawa K, Ishibashi T. Novel mutation in ABCC6 gene in a Japanese pedigree with pseudoxanthoma elasticum and retinitis pigmentosa. *Eye* 2005;**19**:215-17.
- 90 **Le Saux O**, Beck K, Sachsinger C, Silvestri C, Treiber C, Goring HH, Johnson EW, De Paepe A, Pope FM, Pasquali-Ronchetti I, Bercovitch L, Marais AS, Viljoen DL, Terry SF, Boyd CD. A spectrum of ABCC6 mutations is responsible for pseudoxanthoma elasticum. *Am J Hum Genet* 2001;**69**:749-64.
- 91 **Bergen AA**, Plomp AS, Gorgels TG, de Jong PT. [From gene to disease; pseudoxanthoma elasticum and the ABCC6 gene]. *Ned Tijdschr Geneesk* 2004;**148**:1586-9.
- 92 **Hu X**, Peek R, Plomp A, ten Brink J, Scheffer G, van Soest S, Leys A, de Jong PT, Bergen AA. Analysis of the frequent R1141X mutation in the ABCC6 gene in pseudoxanthoma elasticum. *Invest Ophthalmol Vis Sci* 2003;**44**:1824-9.
- 93 **Noji Y**, Inazu A, Higashikata T, Kawashiri M, Katsuda S, Mabuchi H. Two prevalent mutations in the ATP-binding cassette transporters ABCC6 in Japanese patients with pseudoxanthoma elasticum (PXE). *Atherosclerosis Supplements* 2003;**4**:138.
- 94 **Hamlin N**, Beck K, Bacchelli B, Cianciulli P, Pasquali-Ronchetti I, Le Saux O. Acquired Pseudoxanthoma elasticum-like syndrome in beta-thalassaemia patients. *Br J Haematol* 2003;**122**:852-4.
- 95 **Aessopos A**, Farmakis D, Loukopoulos D. Elastic tissue abnormalities resembling pseudoxanthoma elasticum in beta thalassaemia and the sickling syndromes. *Blood* 2002;**99**:30-5.
- 96 **Sherer DW**, Bercovitch L, Lebwohl M. Pseudoxanthoma elasticum: significance of limited phenotypic expression in parents of affected offspring. *J Am Acad Dermatol* 2001;**44**:534-7.
- 97 **Uitto J**, Bernstein EF. Molecular mechanisms of cutaneous aging: connective tissue alterations in the dermis. *J Invest Dermatol Symp Proc* 1998;**3**:41-4.
- 98 **Plomp AS**, Hu X, de Jong PT, Bergen AA. Does autosomal dominant pseudoxanthoma elasticum exist? *Am J Med Genet* 2004;**126A**:403-12.
- 99 **Sherer DW**, Sapadin AN, Lebwohl MG. Pseudoxanthoma elasticum: an update. *Dermatology* 1999;**199**:3-7.
- 100 **Trip MD**, Smulders YM, Wegman JJ, Hu X, Boer JM, ten Brink JB, Zwinderman AH, Kastelein JJ, Feskens EJ, Bergen AA. Frequent mutation in the ABCC6 gene (R1141X) is associated with a strong increase in the prevalence of coronary artery disease. *Circulation* 2002;**106**:773-5.
- 101 **Hu X**, Plomp A, Gorgels T, Brink JT, Loves W, Mannens M, de Jong PT, Bergen AA. Efficient molecular diagnostic strategy for ABCC6 in pseudoxanthoma elasticum. *Genet Test* 2004;**8**:292-300.
- 102 **Bacchelli B**, Quaglino D, Gheduzzi D, Taparelli F, Boraldi F, Trolli B, Le Saux O, Boyd CD, Ronchetti IP. Identification of heterozygote carriers in families with a recessive form of pseudoxanthoma elasticum (PXE). *Mod Pathol* 1999;**12**:1112-23.
- 103 **Uitto J**. Connective tissue biochemistry of the aging dermis. Age-related alterations in collagen and elastin. *Dermatol Clin* 1986;**4**:433-46.
- 104 **Annovazzi L**, Viglio S, Gheduzzi D, Pasquali-Ronchetti I, Zanone C, Cetta G, Iadarola P. High levels of desmosines in urine and plasma of patients with pseudoxanthoma elasticum. *Eur J Clin Invest* 2004;**34**:156-64.
- 105 **Passi A**, Albertini R, Baccarani Contri M, de Luca G, de Paepe A, Pallavicini G, Pasquali-Ronchetti I, Tiozzo R. Proteoglycan alterations in skin fibroblast cultures from patients affected with pseudoxanthoma elasticum. *Cell Biochem Funct* 1996;**14**:111-20.



- 106 **Baccarani-Contri M**, Vincenzi D, Cicchetti F, Mori G, Pasquali-Ronchetti I. Immunochemical identification of abnormal constituents in the dermis of pseudoxanthoma elasticum patients. *Eur J Histochem* 1994;**38**:111–23.
- 107 **Quaglino D**, Boraldi F, Barbieri D, Croce A, Tiozzo R, Pasquali Ronchetti I. Abnormal phenotype of in vitro dermal fibroblasts from patients with Pseudoxanthoma elasticum (PXE). *Biochim Biophys Acta* 2000;**1501**:51–62.
- 108 **Maccari F**, Gheduzzi D, Volpi N. Anomalous structure of urinary glycosaminoglycans in patients with pseudoxanthoma elasticum. *Clin Chem* 2003;**49**:380–8.
- 109 **Aessopos A**, Savvides P, Stamatelos G, Rombos I, Tassiopoulos T, Karagiorga M, Kaklamanis P, Fessas P. Pseudoxanthoma elasticum-like skin lesions and angioid streaks in beta-thalassemia. *Am J Hematol* 1992;**41**:159–64.
- 110 **Baccarani-Contri M**, Bacchelli B, Boraldi F, Quaglino D, Taparelli F, Carnevali E, Francomano MA, Seidenari S, Bettoli V, De Sanctis V, Pasquali-Ronchetti I. Characterization of pseudoxanthoma elasticum-like lesions in the skin of patients with beta-thalassemia. *J Am Acad Dermatol* 2001;**44**:33–9.

### Clinical Evidence—Call for contributors

*Clinical Evidence* is a regularly updated evidence-based journal available worldwide both as a paper version and on the internet. *Clinical Evidence* needs to recruit a number of new contributors. Contributors are healthcare professionals or epidemiologists with experience in evidence-based medicine and the ability to write in a concise and structured way.

#### Areas for which we are currently seeking contributors:

- Pregnancy and childbirth
- Endocrine disorders
- Palliative care
- Tropical diseases

We are also looking for contributors for existing topics. For full details on what these topics are please visit [www.clinicalevidence.com/ceweb/contribute/index.jsp](http://www.clinicalevidence.com/ceweb/contribute/index.jsp)

However, we are always looking for others, so do not let this list discourage you.

#### Being a contributor involves:

- Selecting from a validated, screened search (performed by in-house Information Specialists) epidemiologically sound studies for inclusion.
- Documenting your decisions about which studies to include on an inclusion and exclusion form, which we keep on file.
- Writing the text to a highly structured template (about 1500-3000 words), using evidence from the final studies chosen, within 8-10 weeks of receiving the literature search.
- Working with *Clinical Evidence* editors to ensure that the final text meets epidemiological and style standards.
- Updating the text every 12 months using any new, sound evidence that becomes available. The *Clinical Evidence* in-house team will conduct the searches for contributors; your task is simply to filter out high quality studies and incorporate them in the existing text.

If you would like to become a contributor for *Clinical Evidence* or require more information about what this involves please send your contact details and a copy of your CV, clearly stating the clinical area you are interested in, to [CECommissioning@bmjgroup.com](mailto:CECommissioning@bmjgroup.com).

### Call for peer reviewers

*Clinical Evidence* also needs to recruit a number of new peer reviewers specifically with an interest in the clinical areas stated above, and also others related to general practice. Peer reviewers are healthcare professionals or epidemiologists with experience in evidence-based medicine. As a peer reviewer you would be asked for your views on the clinical relevance, validity, and accessibility of specific topics within the journal, and their usefulness to the intended audience (international generalists and healthcare professionals, possibly with limited statistical knowledge). Topics are usually 1500-3000 words in length and we would ask you to review between 2-5 topics per year. The peer review process takes place throughout the year, and out turnaround time for each review is ideally 10-14 days.

If you are interested in becoming a peer reviewer for *Clinical Evidence*, please complete the peer review questionnaire at [www.clinicalevidence.com/ceweb/contribute/peerreviewer.jsp](http://www.clinicalevidence.com/ceweb/contribute/peerreviewer.jsp)